

## CYBERKNIFE RADIOSURGERY FOR BENIGN MENINGIOMAS: SHORT-TERM RESULTS IN 199 PATIENTS

### Federico Colombo, M.D.

Stereotactic Radiosurgery Center,  
S. Bortolo City Hospital,  
Vicenza, Italy

### Leopoldo Casentini, M.D.

Stereotactic Radiosurgery Center,  
S. Bortolo City Hospital,  
Vicenza, Italy

### Carlo Cavedon, Ph.D.

Department of Medical Physics,  
S. Bortolo City Hospital,  
Vicenza, Italy

### Paolo Scalchi, Ph.D.

Department of Medical Physics,  
S. Bortolo City Hospital,  
Vicenza, Italy

### Stefania Cora, Ph.D.

Department of Medical Physics,  
S. Bortolo City Hospital,  
Vicenza, Italy

### Paolo Francescon, Ph.D.

Department of Medical Physics,  
S. Bortolo City Hospital,  
Vicenza, Italy

### Reprint requests:

Federico Colombo, M.D.,  
Stereotactic Radiosurgery Center,  
S. Bortolo City Hospital,  
Viale Rodolfi 37,  
36100 Vicenza, Italy.  
Email: federico.colombo@ulssvicenza.it

Received, April 4, 2008.

Accepted, October 10, 2008.

Copyright © 2009 by the  
Congress of Neurological Surgeons

**OBJECTIVE:** To present initial, short-term results obtained with an image-guided radiosurgery apparatus (CyberKnife; Accuray, Inc., Sunnyvale, CA) in a series of 199 benign intracranial meningiomas.

**METHODS:** Selection criteria included lesions unsuitable for surgery and/or remnants after partial surgical removal. All patients were either symptomatic and/or harboring growing tumors. Ninety-nine tumors involved the cavernous sinus; 28 were in the posterior fossa, petrous bone, or clivus; and 29 were in contact with anterior optic pathways. Twenty-two tumors involved the convexity, and 21 involved the falx or tentorium. One hundred fourteen patients had undergone some kind of surgical removal before radiosurgery. Tumor volumes varied from 0.1 to 64 mL (mean, 7.5 mL) and radiation doses ranged from 12 to 25 Gy (mean, 18.5 Gy). Treatment isodoses varied from 70 to 90%. In 150 patients with lesions larger than 8 mL and/or with tumors situated close to critical structures, the dose was delivered in 2 to 5 daily fractions.

**RESULTS:** The follow-up periods ranged from 1 to 59 months (mean, 30 months; median, 30 months). The tumor volume decreased in 36 patients, was unchanged in 148 patients, and increased in 7 patients. Three patients underwent repeated radiosurgery, and 4 underwent operations. One hundred fifty-four patients were clinically stable. In 30 patients, a significant improvement of clinical symptoms was obtained. In 7 patients, neurological deterioration was observed (new cranial deficits in 2, worsened diplopia in 2, visual field reduction in 2, and worsened headache in 2).

**CONCLUSION:** The introduction of the CyberKnife extended the indication to 63 patients (>30%) who could not have been treated by single-session radiosurgical techniques. The procedure proved to be safe. Clinical improvement seems to be more frequently observed with the CyberKnife than in our previous linear accelerator experience.

**KEY WORDS:** CyberKnife, Meningioma, Stereotactic radiosurgery

*Neurosurgery* 64:A7-A13, 2009

DOI: 10.1227/01.NEU.0000338947.84636.A6

www.neurosurgery-online.com

Today, single-session stereotactic focused irradiation (radiosurgery) represents a generally accepted treatment alternative for intracranial meningiomas that are not suitable for surgical removal. Since its introduction into clinical practice in 1985, the procedure has proved to be safe and reliable. Reported results, in terms of clinical stabilization and tumor growth control, seem to be relatively independent of the machine used (either gamma knife or modified linear accelerator [LINAC]); many reports point to 5-year control rates of more

than 95%, with a low or very low treatment-related complication rate. This rate of success represents the procedure's "gold standard" (10–13, 17, 19–23, 26, 27, 31, 32, 40).

Although the procedure has proved to be effective, some limitations and drawbacks are still present today. As a common feature of single-session radiosurgery, large tumors cannot be irradiated, owing to the increased risk of treatment-related complications. Moreover, long-lasting tumor control seems to be more difficult to attain (8, 21).

**ABBREVIATIONS:** CI, conformality index; CT, computed tomographic; DMAX, maximum dose; DPI, dose at the prescription isodose; HI, homogeneity index; LINAC, linear accelerator; mCI, modified conformality index; MRI, magnetic resonance imaging; PIV, prescription isodose volume; 3D, 3-dimensional; TV, tumor volume

The CyberKnife (Accuray, Inc., Sunnyvale, CA) is a dedicated radiosurgery apparatus using a radiation source (a 6-MV LINAC) mounted on a frameless, image-guided, computer-operated robot (1, 2, 4, 5, 30). We thought that this apparatus could afford significant improvements in the procedure, and we used it in meningioma radiosurgery. The aim of this article is to describe the results obtained with the CyberKnife in intracranial meningioma radiosurgery and to discuss possible advantages connected to the peculiar features of this robotic radiosurgery system.

## PATIENTS AND METHODS

From January 2003 to December 31, 2007, 218 patients affected by extracerebral tumors of meningeal origin were treated in our center. This report deals with 199 patients affected by intracranial benign meningiomas that were deemed to be World Health Organization Grade I (16). Patients with Grade II (atypical) and III (malignant) meningiomas were excluded. In 85 patients, the diagnoses of benign meningiomas were based only on imaging appearance and clinical evolution (10, 21).

The intended goals of the treatment were long-term prevention of tumor growth, maintenance of patient function and quality of life, and prevention of new neurological deficits (19, 22). Entry criteria for treatment were lesions unsuitable for surgery and/or remnants after partial surgical removal. All patients were either symptomatic and/or harboring growing tumors. Radiosurgery was offered to patients who refused open surgery (if feasible) and who asked for a less invasive treatment procedure.

Radiosurgery was considered contraindicated in the presence of cerebral edema with significant mass effect and/or acute symptomatic compression of brainstem or optic pathways. For these patients, microsurgical decompression or removal was strongly suggested. Radiosurgical treatment was also considered futile in patients with long-lasting stable disease without any sign of clinical or radiological progression.

Treatment planning was performed on contrast-enhanced magnetic resonance imaging (MRI) fused to the computed tomographic (CT) scan. Automatic target delineation was routinely used, whereas automatic delineation of critical structures (motor cortex and language areas) was used in 5 critically located meningiomas. In meningioma radiosurgery, the definition of target outline and nearby critical structures requires contrast-enhanced MRI; this imaging modality was routinely used except in patients with claustrophobia or other contraindications to the exposure of magnetic fields or gadolinium. Contrast-enhanced MRI is coregistered to the CT scan used for image guidance, and it is used for treatment planning with an original procedure that allows the evaluation of coregistration accuracy. The procedure was developed for using 3-dimensional (3D) rotational angiography in arteriovenous malformation radiosurgery (39). It can also be used for other pathologies, allowing fusion between different types of 3D imaging modalities, such as MRI, CT-positron emission tomography, and functional MRI (38).

Once registered data sets have been imported into the CyberKnife treatment planning system, automatic delineation of the tumor contour can be performed, slice by slice, on axial sections of MRI scans and/or contrast-enhanced CT scans, using an automatic contouring tool with an appropriate threshold on voxel values that immediately delineate the target boundaries and reconstruct the tumor volume in 3D space. The same image registration procedure can be used for implementing functional MRI in treatment planning and for automatic contouring of critical regions (motor strip, language cortical areas, and so forth).

The radiation dose to be delivered to the target volume and dose limits to critical structures are then decided, according to general radiosurgery experience. The optimal collimator dimension is selected accord-

ing to the volume and shape of the target, usually depending mainly on the minimum target cross sectional dimension. Finally, an inverse planning optimization procedure can be started. The CyberKnife G3 robotic arm can move the LINAC to 100 fixed positions (nodes), evenly spaced in a virtual hemisphere surrounding the target. From each of these nodes, 12 radiation beams with different angular directions can be used (a total of 1200 radiation beams). We used this apparatus until August 2007, when we upgraded our system to the G4 level. The CyberKnife G4 has 130 nodes, and the total number of usable beams is increased proportionally. In both apparatuses, inverse treatment planning determines the radiation dose and the angular direction of each individual radiation beam that are adequate for satisfying the dose prescriptions (1–5).

Treatment planning is evaluated by standard radiobiological indexes (29, 35):  $CI = TV/TVP_{IV}$  (where CI is the conformality index, TV is the tumor volume, and  $TVP_{IV}$  is the volume of the target covered by the prescription isodose);  $mCI = TV \times PIV/TVP_{IV}^2$  (where mCI is the modified conformality index, and PIV is the prescription isodose volume), and  $HI = DMAX/DPI$  (where HI is the homogeneity index, DMAX is the maximum dose, and DPI is the dose at the prescription isodose).

After physician evaluation and acceptance of the proposed solution, the irradiation procedure can be undertaken. The patient is fixed in the treatment position using a standard thermoplastic face mask immobilization system that limits the displacement of the head into the range in which the image-guided robot can correct for involuntary movements during the procedure. In cases of fractionated treatments, once the session is terminated, the face mask is stored and used again for subsequent fractions (1, 2, 4).

Treated target volumes varied from 0.1 to 64 mL, and radiation doses ranging from 11 to 25 Gy were delivered at treatment isodoses of 70 to 90%. Single-session irradiation was used in patients with small tumors, at a safe distance (>3 mm) from the brainstem or optic pathways. In patients with lesions larger than 8 mL and/or close to important critical structures, the dose was administered in 2 to 5 daily fractions. Prescription doses were calculated to be roughly equivalent to 11 to 12 Gy in a single fraction, considering an  $\alpha/\beta$  ratio of 3 for meningiomas (1, 36). We always tried to reduce the dose absorbed by any portion of the anterior optic pathways to less than 7 Gy per session. In patients in whom the adjacent critical structure was impossible to locate, the structure was considered to be exposed to radiation doses equal to those delivered to the periphery of the tumor. The location of the point of maximal dose was always checked, and when it was found to be close to the surface of the tumor where the critical structure could be located, the plan was modified to move it to a more safe, central tumor location. Treatment planning for recurrences after failed radiosurgery was undertaken, taking into account the previous irradiation. Recurrences outside the previous target volume (out-field recurrences) were treated with the same doses as those used in this series. Tumors displaying failure of growth control inside the previously irradiated target (in-field recurrences) were treated with a slightly lower dose (15–20% less than that considered for first-time radiosurgery).

Our follow-up protocol dictates MRI evaluation at 3, 6, 12, 18, and 24 months after treatment, and yearly controls thereafter. The clinical picture and visual field examination (for periorbital lesions) were assessed every 6 months after irradiation for the first 2 years, and every year thereafter. Tumor control was considered attained until the appearance of tumor volume increase and/or clinical worsening.

## RESULTS

The male-to-female ratio for this series was 56:143. The ages of the patients ranged from 15 to 83 years (mean, 55.8 years). Before CyberKnife treatment, 114 patients (57.3%) underwent

partial microsurgical removal. All patients were either symptomatic and/or harboring growing tumors. Eight patients refused open surgery and asked for radiosurgery. Eleven recurrences after failed previous radiosurgery were also treated; 6 patients displayed unrestrained tumor progression after multiple-arc LINAC radiosurgery. Two patients had undergone previous gamma knife radiosurgery elsewhere. Three patients in the present series who showed tumor progression were re-treated 14, 18, and 30 months after the first CyberKnife radiosurgery.

Regarding tumor location, large tumors frequently involved more than a single region, and precise anatomic landmarks were often trespassed. Nevertheless, the principal or initial site of growth was considered to be the cavernous sinus in 99 tumors; 28 grew from the dura of the posterior fossa, petrous bone, or clivus; and 29 abutted the anterior optic pathways coming from the dura of the orbit, planum sphenoidale, tuberculum sellae, or anterior clinoid process. Twenty-two tumors involved the dural convexity, and 21 involved the falx or tentorium.

Treated target volumes varied from 0.1 to 64 mL (mean, 7.5 mL; median, 6.8 mL), and radiation doses ranging from 11 to 25 Gy (mean, 18.5 Gy) were delivered at the treatment isodose. Single-session irradiation was used in 49 patients with small tumors, at a safe distance (>3 mm) from the brainstem or optic pathways. In 150 patients with lesions that were larger than 8 mL and/or close to important critical structures, the dose was administered in 2 (32 patients), 3 (76 patients), 4 (18 patients), and 5 (24 patients) daily fractions (Table 1).

Treatment planning was evaluated by radiobiological indexes, as described in the previous section. The conformality index ranged from 1.01 to 1.48 (mean, 1.18), the modified conformality index ranged from 1.14 to 1.52 (mean, 1.29), and the homogeneity index ranged from 1.18 to 2.01 (mean, 1.35).

Follow-up ranged from 1 to 59 months (mean, 30 months; median, 30 months). Clinical data are available for 191 patients (111 patients with follow-up longer than 24 months and 142 patients with follow-up longer than 12 months). We did not observe any kind of acute treatment-related neurological complications.

Tumor volume decreased in 36 patients; in most patients, the observed decrease of volume was in the range of 10 to 25%. In only 3 patients was there an exceptional (>50%) volume decrease; the most striking case is displayed in Figure 1. Tumor volume was unchanged in 148 patients and increased in 7

(tumor progression). Three patients underwent repeated radiosurgery, and 4 patients underwent operations. From a clinical point of view, 154 patients were unchanged. In 34 patients, a significant improvement in clinical symptoms (proptosis in 4, headache in 7, visual function in 2, oculomotor function in 10, and trigeminal pain in 9) was obtained. The onset of improvement appeared from 3 to 18 months after irradiation. In 6 patients, clinical deterioration was observed. Two patients with a superficial lesion had transient limited hair loss. One patient with tumor progression displayed new cranial deficits (facial nerve impairment Grade II and trigeminal dysesthesia). In 2 patients, diplopia worsened (1 with increased tumor volume). Two patients had visual field reduction (both with increased tumor volume), and 1 patient had worsened headache (Table 2). In all patients, except in the patient with new cranial nerve deficits, the worsening of the clinical picture could be related to direct radiation effects (0.5% complication rate).

Treatment failures seem to be unrelated to the fractionation scheme (3 progressions in 49 patients treated with single-session irradiation, and 4 of 150 patients treated with 2–5 fractions) or to tumor dimensions (3 patients with failed control in tumors larger than the median, and 4 patients with tumors smaller than the median tumor volume of the entire series, 6.8 mL).

Time to tumor progression was coded at the time of the first imaging study that showed tumor volume increase. Kaplan-Meier evaluation of the progression-free survival (15) demonstrated a 93.56% control rate at the 5-year follow-up point (Fig. 2).

## DISCUSSION

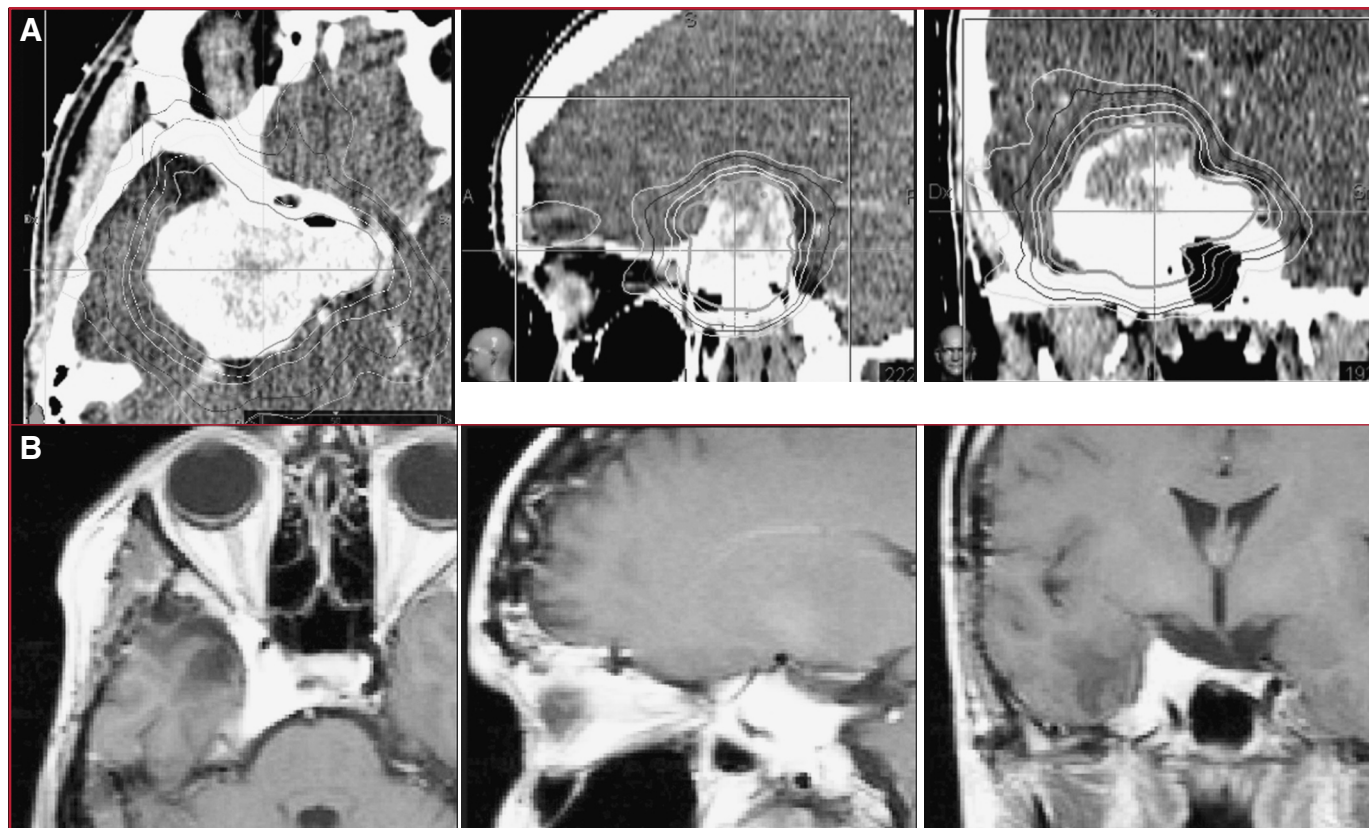
### Indications for Surgery/Radiosurgery

Although meningiomas have some characteristics that make them ideal targets for stereotactic radiosurgery (clear-cut, infiltration-free boundaries, ideal visibility on contrast-enhanced examinations, slow progression that allows time for radiosurgery effect), they were not considered among the possible indications by the pioneers of the method. At that time, surgery was considered the only way to deal with these benign tumors, and complete surgical resection with the associated dural base was considered the goal in every patient with relevant morbidity. The first meningioma patient treated by radiosurgery (an angioblastic meningioma of the cavernous sinus, recurrent after surgery) was reported by our group in 1985 (6, 7).

**TABLE 1. Fractionation distribution<sup>a</sup>**

No. of fractions	No. of patients	Total dose, range (Gy)	BED, $\alpha/\beta = 2$ (Gy)	BED, $\alpha/\beta = 3$ (Gy)
1	49	11–13	71.5–97.5	51.3–69.3
2	32	14–17	63–89.2	46.6–65.1
3	76	16–20	58.4–86.6	44.2–64
4	18	18–23	58.5–89.1	45–67.8
5	24	19–25	64.1–87.5	49–66.7

<sup>a</sup> BED, biological equivalent dose.



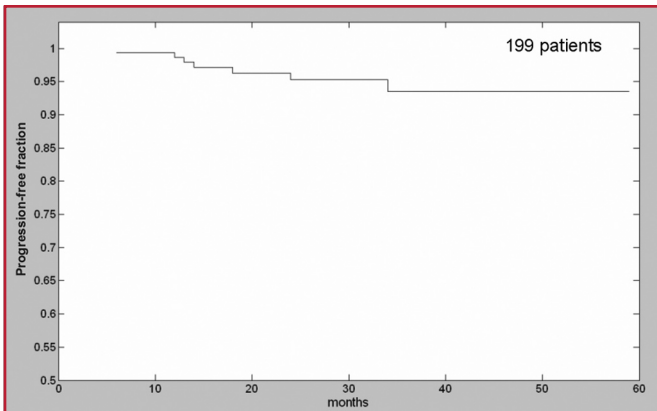
**FIGURE 1.** A 28-year-old woman presented with a postoperative recurrence of a cavernous sinus meningioma (volume, 36 mL). The patient experienced diplopia and visual field reduction. Treatment was 20 Gy, conformal plan, delivered in 5 fractions. **A**, computed tomographic scans showing treatment plan. Isodose lines: 80% (prescription isodose), orange; 60%, violet; 30%, light blue. **B**, magnetic resonance imaging scans 24 months after treatment showing normal clinical appearance.

It was after publication of the landmark article by Kondziolka et al. (20) in 1991 that this indication became gradually more popular, and meningiomas now represent one of the more frequent indications for stereotactic irradiation. Interest in the use of stereotactic radiosurgery is proven by a large mass of publications dealing with the different aspects of this practice, starting with indications and finishing with results that are obtainable. Today, there are excellent articles on long-term experience in dealing with several hundreds of patients, the vast majority of them treated by gamma knife groups, but some of them treated by modified LINACs (10–13, 17, 19–23, 26, 27, 31–33, 40). The most controversial point of this practice, the relative indications for surgery and radiosurgery, has been the object of a long debate. Two of the most appreciated grading systems introduced by general neurosurgeons for predicting the extent of resection and the outcome of surgery strongly supported the view of as complete a removal as possible, and they defined, as limitations to this achievement, vessel encasement, cranial nerve involvement, unfavorable imaging, and, of course, previous radiosurgery (24, 32). Recently, an open attitude seems to be more prevalent (14).

Regarding relative indications for microsurgical removal and radiosurgery and/or possible combination strategies using the 2 treatment modalities, a large number of reports have been presented. Today, there is a general agreement on a strategy of complete microsurgical removal when a low probability of complications exists and a judicious combination of microsurgery and radiosurgery when complete removal would likely be accompanied by a high rate of complications (18, 25). Good indications for surgery/radiosurgery have been defined as follows: for minimal lesions (<2 cm) that are clinically and radi-

**TABLE 2. Clinical evolution after radiosurgery**

Symptoms	No. of patients	Improved	Unchanged	Worsened
Ocular movements	90	12	76	2
Visual function	65	2	61	2
Exophthalmos	36	4	32	0
Pain	37	16	20	1



**FIGURE 2.** Graph showing progression-free survival of the entire series (199 patients) evaluated using the Kaplan-Meier method.

ologically stable: observation; for small (<3 cm) tumors that are confined to the cavernous sinus and distant from the optic pathways and brainstem: primary radiosurgery; for large tumors (>3 cm) that are attached to or compressing the optic pathways: radical surgery or decompression, followed by radiosurgery; and for larger tumors associated with optic nerve encasement, neural cavernous infiltration, cranial base dural spreading (Sekhar Grades 4–6), or likely malignancy: surgical debulking, followed by adjuvant treatments (mainly fractionated radiation therapy) (25, 26).

The introduction of the CyberKnife significantly impacts the tenets of radiosurgery indications. In the absence of symptomatic compression of the brainstem or optic pathways or acute mass effect, hypofractionated radiosurgery can safely be applied to lesions larger than 3 cm in diameter (>13.5 mL). In our series, we treated a group of 63 patients who had lesions of more than 13.5 mL (34 patients), were lacking a safe distance (<3 mm) from the optic pathways (29 patients), or both. In our opinion, it would have been impossible to treat these patients by means of our previous single-session, frame-based procedure without accepting a high risk of complications. With increasing experience, fractionated schemes were extended to tumors close to critical structures other than the optic pathways (brainstem; cranial nerves; and motor, visual, and language cortex). By use of 2 to 5 fractions, we have treated lesions measuring up to 65 mL without neurological complications and with a probability of consistent tumor control that is not significantly different from that obtainable in small (<3 cm) meningiomas. The possibility of extending the limit on the volume of lesions treatable with radiosurgery may also simplify the task of the surgeon, who today must perform a potentially dangerous removal until only a small remnant is left, but tomorrow may be allowed to leave tumors of up to 4 to 5 cm to radiosurgery, once efficient debulking and critical structure decompression have been attained.

### Tumor Control

Long-lasting tumor control has been the main goal in meningioma radiosurgery since the beginning and, in the absence of

characteristic imaging modifications, the only way to assess the success of the treatment. Usually, progression-free survival, ascertained using the Kaplan-Meier method (15), has been used to plot the probability of tumor control in relation to time elapsed since radiosurgery. Recently, Nicolato et al. (28) proposed induced modifications in functional imaging (single-photon emission computed tomography with a  $^{111}\text{In}$ -labeled somatostatin analog) as a way to ascertain a positive response to treatment, but their interesting suggestions have not been followed thus far. As the 5- and 10-year progression-free percentage remains the main index for measuring radiosurgery success, 5-year control in recent literature seems to range from 87 to 98%, according to different authors (10–13, 17, 19–23, 26, 27, 31–33, 40). A selection of these outcomes is summarized in Table 3.

Because of the restricted length of our follow-up periods, we can present only initial short-term results. With meningiomas, a longer follow-up period would be necessary to definitively ascertain treatment efficacy. However, the Kaplan-Meier evaluation of our series seems to point to 93% progression-free survival at the time of the 5-year follow-up evaluation. In these terms, the progression-free fraction seems to be only slightly inferior to the best gamma knife series. On the other hand, the CyberKnife has the obvious advantage of being a less invasive procedure, allowing the same precision as a frame-based technique (1, 2).

Regarding tumor control, 2 factors must be taken into account to make an objective comparison. First of all, we usually treat lesions that are larger and closer to clinical structures than those usually selected for gamma knife treatment. Target volume seems to be the most important factor for predicting meningioma response to radiosurgery (8, 19). In all of our patients, the volumes of the targets were evaluated in 3D imaging data sets (usually contrast-enhanced MRI scans), and measurements were made on tumors delineated by the automatic method described previously (9). The automatic method avoids any operator variability and, in our experience, usually measures volumes that are smaller than those delineated manually. In our series, a relatively large number of patients harbored lesions greater than 10 mL in volume; such lesions are usually not considered good candidates for radiosurgery. DiBiase et al. (8) found 68% progression-free survival in patients with lesions of more than 10 mL, versus 91% in those with target volumes of less than 10 mL, and this difference was found to be statistically significant. In contrast, our results seem to be uninfluenced by tumor volume.

The second issue to be taken into account is the fact that a large fraction (43%) of our patients were treated on a diagnosis of benign meningioma based only on imaging studies; consequently, histological verification was not available in these patients. The lack of histological verification may obscure the results of the procedure. This limitation, however, may only lead to a bias against radiosurgery, because of the presumption that all treated tumors were benign and that, on the other hand, patients harboring more aggressive tumors could not have been identified and excluded from evaluation. As demonstrated by Flickinger et al. (10), tumor control probability in imaging-diagnosed patients may be lower than that obtained in surgically verified benign meningiomas.

**TABLE 3. Summary of recently published series for meningioma radiosurgery<sup>a</sup>**

Series (ref. no.)	System	No. of patients	Follow-up (mo)	PFS 5 y	Morbidity <sup>b</sup>
Roche et al., 2000 (32)	GKS	92	30 median	94%	2%
Nicolato et al., 2002 (27)	GKS	122	48 median	96%	2.5%
Pollock, 2003 (31)	GKS	330	43 mean	94%	8%
Kreil et al., 2005 (22)	GKS	200	94 median	98.5%	4.5%
Malik et al., 2005 (26)	GKS	309	96 median	87%	3%
Hasegawa et al., 2007 (13)	GKS	115	62 median	94%	5.5%
Kollová et al., 2007 (17)	GKS	368	60 median	97.9%	5.7%
Kondziolka et al., 2008 (21)	GKS	972	48 median	97%	7.7%
Villavicencio et al., 2001 (40)	LINAC	56	60 median	95%	9%
Friedman et al., 2005 (11)	LINAC	210	39 mean	96%	2.3%
Selch et al., 2004 (34)	FSRT	45	36 median	97.4%	2.1%
Hamm et al., 2008 (12)	FSRT	183	36 median	96.9%	3.8%
Adler et al., 1999 and 2006 (1, 2)	CKS	27	49 mean	—	1%
Current series	CKS	199	30 median	93.5%	0.5%

<sup>a</sup> PFS, progression-free survival; GKS, gamma knife; LINAC, linear accelerator; FSRT, fractionated stereotactic radiotherapy; CKS, CyberKnife.

<sup>b</sup> Radiation-related permanent morbidity.

In 2 reported series of patients treated with fractionated stereotactic radiotherapy (with standard fractionation and the use of a relocatable frame), tumor control at 5 years seems to be slightly higher than that we were able to obtain in our patients (Table 3) (12, 34). In those series, large tumor volumes of up to 75 mL were treated (12). On the other hand, the frequency of reported adverse effects in those studies was also higher than what we observed in our series. At least a part of the complications could be a result of the inferior precision of relocatable head frames in comparison to that provided by standard head frames. Accurate positioning is also influenced by sustained, long-lasting patient cooperation. The correct position is measured at the beginning of each fraction, and there is no online verification during the treatment session, such as that provided by CyberKnife continuous image guidance and robot adjustments. Minor target shifts occurring during treatment cannot be ascertained and corrected.

### Optic Tolerance

The reported incidence of radiation-induced optic neuropathy in routine radiosurgical treatment of meningiomas may vary between 1.1 and 1.4% when a cutoff exposure dose of 11 Gy/15 mm<sup>3</sup> in adults, and 8 to 9 Gy in children, is adopted (3, 37). This is confirmed by studies on fractionated radiation therapy isoeffective doses, given an  $\alpha/\beta$  factor of 2.7 to 3.8 (36).

The introduction of the CyberKnife may represent an important issue regarding generally accepted indications for radiosurgery. Cranial tracking, using skeletal anatomy to position the radiation beam, is as precise as frame-based approaches and eliminates the need for a head frame (1, 2). Consequently, it is possible to revert to hypofractionated regimens without deterioration of spatial accuracy and, in our

experience, without influence on the probability of tumor control. Fractionation has been proposed to decrease the risk of complications, especially in perioptic lesions, allowing the treatment of tumors that are in direct contact with optic pathways in patients in whom they are not clearly identifiable in images used for treatment planning (2). The small number of fractions possible with the CyberKnife (up to 5) has been advocated by Shrieve et al. (36) as an effective way to decrease visual complications in stereotactic radiosurgery of parasellar meningiomas. They calculated that using equivalent biological doses in a small number of fractions continues to exceed optic tolerances until at least 25 fractions are applied. In contrast to these data, Adler et al. (1) reported a clinical experience of 49 patients affected by perioptic lesions, 27 of them being meningiomas. With a mean follow-up period of 4 years (<24 months in 2 patients), 38 patients (78%) remained stable, 8 patients (16%) improved, and 3 patients (6%) worsened, 2 of them for tumor progression (incidentally, both tumors were meningiomas). The real rate of treatment-related complications is consequently 2% (1 case). Our results seem to confirm that hypofractionation can not only decrease the risk of visual complications, but also improve, in a limited but significant number of patients, visual function, a result seldom observed after single-session radiosurgery.

### CONCLUSION

In relation to isocentric, single-session LINAC radiosurgery, which we used until 2003, the use of the CyberKnife expanded the indications for radiosurgery to include more than 30% of patients who could not have been treated by our frame-based procedure. From a clinical point of view, the follow-up period was too short to definitively evaluate the efficacy of the

method. However, some conclusions can be drawn. We observed very few treatment-related complications (only 1 neurological), even in large tumors. Moreover, clinical improvement (pain, ocular movements, and, in a small number of patients, visual function) seemed to be more frequently observed. CyberKnife radiosurgery for meningiomas proved to be effective and safe. The tumor control rate was not significantly different for small and large tumor volumes or single- and multiple-session treatments.

## Disclosure

The authors have no personal financial or institutional interest in any of the drugs, materials, or devices described in this article.

## REFERENCES

- Adler JR Jr, Gibbs IC, Puataweepong P, Chang SD: Visual field preservation after multisession CyberKnife radiosurgery for perioptic lesion. *Neurosurgery* 59:244–254, 2006.
- Adler JR Jr, Murphy MJ, Chang SD, Hancock SL: Image-guided robotic radiosurgery. *Neurosurgery* 44:1299–1307, 1999.
- Carvounis PE, Katz B: Gamma knife radiosurgery in neuro-ophthalmology. *Curr Opin Ophthalmol* 14:317–324, 2003.
- Chang SD, Adler JR Jr: Treatment of cranial base meningiomas with linear accelerator radiosurgery. *Neurosurgery* 41:1019–1027, 1997.
- Collins SP, Coppa ND, Zhang Y, Collins BT, McRae DA, Jean WC: CyberKnife radiosurgery in the treatment of complex skull base tumors: Analysis of treatment planning parameters. *Radiat Oncol* 1:46, 2006.
- Colombo F, Benedetti A, Pozza F, Zanardo A, Avanzo RC, Chiarego G, Marchetti C: Stereotactic radiosurgery utilizing a linear accelerator. *Appl Neurophysiol* 48:133–145, 1985.
- Colombo F, Pozza F, Chiarego G: Linear accelerator radiosurgery: Current status and perspectives, in Lunsford LD (ed): *Stereotactic Radiosurgery Update*. New York, Elsevier, 1992, pp 37–46.
- DiBiase SJ, Kwok Y, Yovino S, Arena C, Naqvi S, Temple R, Regine WF, Amin P, Guo C, Chin LS: Factors predicting local tumor control after gamma knife stereotactic radiosurgery for benign intracranial meningiomas. *Int J Radiat Oncol Biol Phys* 60:1515–1519, 2004.
- Feigl GC, Samii M, Horstmann GA: Volumetric follow-up of meningiomas: A quantitative method to evaluate treatment outcome of gamma knife radiosurgery. *Neurosurgery* 61:281–287, 2007.
- Flickinger JC, Kondziolka D, Maitz AH, Lunsford LD: Gamma knife radiosurgery of imaging diagnosed intracranial meningioma. *Int J Radiat Oncol Biol Phys* 56:801–806, 2003.
- Friedman WA, Murad GJ, Bradshaw P, Amdur RJ, Mendenhall WM, Foote KD, Bova FJ: Linear accelerator radiosurgery for meningiomas. *J Neurosurg* 103:206–209, 2005.
- Hamm K, Henzel M, Gross MW, Surber G, Kleinert G, Engenhart-Cabillie R: Radiosurgery/stereotactic radiotherapy in the therapeutical concept for skull base meningiomas. *Zentralbl Neurochir* 69:14–21, 2008.
- Hasegawa T, Kida Y, Yoshimoto M, Koike J, Iizuka H, Ishii D: Long-term outcomes of gamma knife surgery for cavernous sinus meningiomas. *J Neurosurg* 107:745–751, 2007.
- Heros RC: Radiosurgery and neurosurgeons. *J Neurosurg* 103:203–205, 2005.
- Kaplan E, Meier P: Nonparametric estimation from incomplete observations. *J Am Stat Assoc* 53:457–481, 1958.
- Kleihues P, Louis DN, Scheithauer BW, Rorke LB, Reifenberger G, Burger PC, Cavenee WK: The WHO classification of tumors of the nervous system. *J Neuropathol Exp Neurol* 61:215–229, 2002.
- Kollová A, Liscák R, Novotný J Jr, Vladyka V, Simonová G, Janousková L: Gamma knife surgery for benign meningiomas. *J Neurosurg* 107:325–336, 2007.
- Kondziolka D, Flickinger JC, Perez B: Judicious resection and/or radiosurgery for parasagittal meningiomas: Outcomes from a multicenter review. *Neurosurgery* 43:405–414, 1998.
- Kondziolka D, Levy EI, Niranjan A, Flickinger JC, Lunsford LD: Long term outcomes after meningioma radiosurgery: Physician and patient perspectives. *J Neurosurg* 91:44–50, 1999.
- Kondziolka D, Lunsford LD, Coffey RJ, Flickinger JC: Stereotactic radiosurgery of meningiomas. *J Neurosurg* 74:552–559, 1991.
- Kondziolka D, Mathieu D, Lunsford LD, Martin JJ, Madhok R, Niranjan A, Flickinger JC: Radiosurgery as definitive treatment of intracranial meningiomas. *Neurosurgery* 62:53–60, 2008.
- Kreil W, Luggin J, Fuchs I, Weigl V, Eustacchio S, Papaefthymiou G: Long term experience of gamma knife radiosurgery for benign skull base meningiomas. *J Neurol Neurosurg Psychiatry* 76:1425–1430, 2005.
- Lee JY, Kondziolka D, Flickinger JC, Lunsford LD: Radiosurgery for intracranial meningiomas. *Prog Neurol Surg* 20:142–149, 2007.
- Levine ZT, Buchanan RI, Sekhar LN, Rosen CL, Wright DC: Proposed grading system to predict the extent of resection and outcomes for cranial base meningiomas. *Neurosurgery* 45:221–230, 1999.
- Linskey ME, Davis SA, Ratanatharathorn V: Relative roles of microsurgery and stereotactic radiosurgery for the treatment of patients with cranial meningiomas: A single surgeon 4-year integrated experience with both modalities. *J Neurosurg* 102 [Suppl]:59–70, 2005.
- Malik I, Rowe JG, Walton L, Radatz MW, Kemeny AA: The use of stereotactic radiosurgery in the management of meningiomas. *Br J Neurosurg* 19:13–20, 2005.
- Nicolato A, Foroni R, Alessandrini F, Bricolo A, Gerosa M: Radiosurgical treatment of cavernous sinus meningiomas: Experience with 122 treated patients. *Neurosurgery* 51:1153–1161, 2002.
- Nicolato A, Giorgetti P, Foroni R, Grigolato D, Pasquin IP, Zuffante M, Soda C, Tomasini A, Gerosa M: Gamma knife radiosurgery in skull base meningiomas: A possible relationship between somatostatin receptor decrease and early neurological improvement without tumor shrinkage at short-term imaging follow-up. *Acta Neurochir (Wien)* 147:367–375, 2005.
- Paddick I: A simple scoring ratio to index the conformity of radiosurgical treatment plans. *J Neurosurg* 93 [Suppl]:219–222, 2000.
- Pham CJ, Chang SD, Gibbs IC, Jones P, Heilbrun MP, Adler JR Jr: Preliminary visual field preservation after staged CyberKnife radiosurgery for peri-optic lesion. *Neurosurgery* 54:799–812, 2004.
- Pollock BE: Stereotactic radiosurgery for intracranial meningiomas: Indications and results. *Neurosurg Focus* 14:e4, 2003.
- Roche PH, Régis J, Dufour H, Fournier HD, Delsanti C, Pellet W, Grisoli F, Peragut JC: Gamma knife radiosurgery in the management of cavernous sinus meningiomas. *J Neurosurg* 93 [Suppl]:68–73, 2000.
- Saberi H, Meybodi AT, Rezai AS: Levine-Sekhar grading system for prediction of the extent of resection of cranial base meningiomas revisited: Study of 124 cases. *Neurosurg Rev* 29:138–144, 2006.
- Selch MT, Ahn E, Laskari A, Lee SP, Agazaryan N, Solberg TD, Cabatan-Awang C, Frighetto L, Desalles AA: Stereotactic radiotherapy for treatment of cavernous sinus meningiomas. *Int J Radiat Oncol Biol Phys* 59:101–111, 2004.
- Shaw E, Kline R, Gillin M, Souhami L, Hirschfeld A, Dinapoli R, Martin L; Radiation Therapy Oncology Group: Radiosurgery quality assurance guidelines. *Int J Radiat Oncol Biol Phys* 27:1231–1239, 1993.
- Shrieve DC, Hazard L, Boucher K, Jensen RL: Dose fractionation in stereotactic radiotherapy for parasellar meningiomas: Radiobiological considerations of efficacy and optic nerve tolerance. *J Neurosurg* 101 [Suppl]:390–395, 2004.
- Stafford SL, Pollock BE, Leavitt JA, Foote RL, Brown PD, Link MJ, Gorman DA, Schomberg PJ: A study on radiation tolerance of the optic nerve and chiasm after stereotactic radiosurgery. *Int J Radiat Oncol Biol Phys* 55:1177–1181, 2003.
- Stancanello J, Cavedon C, Francescon P, Causin F, Avanzo M, Colombo F, Cerveri P, Ferrigno G, Uggeri F: BOLD fMRI integration into radiosurgery treatment planning of cerebral vascular malformations. *Med Phys* 34:1176–1184, 2007.
- Stancanello J, Cavedon C, Francescon P, Cerveri P, Ferrigno G, Colombo F, Perini S: Development and validation of a CT-3D rotational angiography registration method for AVM radiosurgery. *Med Phys* 31:1363–1371, 2004.
- Villavicencio AT, Black PM, Shrieve DC, Fallon MP, Alexander E, Loeffler JS: Linac radiosurgery for skull base meningiomas. *Acta Neurochir (Wien)* 143:1141–1152, 2001.